

HISTOGENESIS OF HUMAN FOETAL CEREBELLAR CORTEX

Krishna veni. S¹, Raju Sugavasi², Subhadra Devi .V³

1. M.Sc. Medical Anatomy, Tutor, Department of Anatomy, Fathima Institute of Medical sciences (FIMS), Kadapa- 516003. Andhra Pradesh. India.
2. BPT, M.Sc. Medical Anatomy, Assistant Professor, Department of Anatomy, Fathima Institute of Medical sciences (FIMS), Kadapa- 516003. Andhra Pradesh. India.
3. MS Anatomy, Professor & HOD, Department of Anatomy, Sri Padmavathi medical college for women, Sri venkateswara institute of medical sciences (SVIMS), Tirupathi, AndhraPradesh, India.

Correspondence to

Raju Sugavasi , (BPT, M.Sc. Medical Anatomy.) Assistant Professor, Department of Anatomy, Fathima Institute of Medical sciences (FIMS)Kadapa, 516003, Andhra Pradesh, India.Ph No: +91-9849501978, E –Mail: - anatraju@yahoo.co.in

ABSTRACT

The objective of present study is to describe the prenatal histogenesis of human cerebellar cortex. The aim of this study is to demonstrate the various histological features of human foetal cerebellum in spontaneously aborted fetuses of different gestational ages for analyzing the cerebellar histology. Histogenesis of cerebellum is observed from 13 weeks to 36 weeks of gestational age by dividing the specimens into six gestational age groups (group A to group F). External granular layer is observed at 13 weeks of gestation and purkinje cell layer is arranged at 17 weeks as a multilayered and single layer at 36 weeks of gestation. The knowledge of cerebellar anatomy has a tremendous neurosurgical importance. Future investigations might involve evaluation of the cerebellum at other gestational ages.

Key words: Cerebellum, Histogenesis, Purkinje cell

INTRODUCTION

Cerebellum is one of the structure in the brain that begins first to differentiate but last to mature since its development is spread over a longer period and shows age related changes (Standing et al, 2008). Cerebellar cortex is divided into outer molecular layer, middle Purkinje cell layer and inner granular layer. External granular layer appears first on the surface of the cerebellum as a dense layer of cells at third embryonic month. External granular was precisely described by Obersteinerand, he

observed that the cells in the outer layer form the basal membrane and cells of the inner layer enter into the molecular layer and migrate through this into the inner granular layer. External granular layer consists of indifferent cells that may convert into either nerve cells or glial cells, (Schaper 1894). External granular layer is the precursor of purkinje cell and internal granular cell layer, (Popoff 1895).

MATERIALS AND METHODS

A total of forty-four dead and spontaneously aborted fetuses of the both sexes along with relevant obstetric history were collected from the Department of Obstetrics and Gynaecology, Government Maternity Hospital, Sri Venkateswara Medical College, Tirupati, Andhra Pradesh, India, after taking permission given by the Institutional ethical committee. 44 aborted fetuses, ranging from 13-36 weeks gestational age, in which the males fetuses are 18 and the female fetuses are 26. Gestational age of Fetuses is identified by measuring their Crown- rump and Crown- heel length. Total number of fetuses is categorized into 6 gestational age

groups 13-16, 17-20, 21-24, 25-28, 29-32 and 33-36 weeks.

Dissected foetal cerebellum specimens are subjected to routine histological processing. The obtained paraffin tissue blocks were cut in to 5µm thickness and stained with eosin and Haematoxylin. Then the mounted sections were observed under low power and high power objectives of binocular light microscope for histological features of the cerebellum like developmental changes occurs in the arrangement of layers (Molecular layer, Purkinje cell layer and Granular layer). The histological sections were photographed through microscope.

RESULTS

In the present study, histogenesis of cerebellar cortex was observed from 13 weeks to 36 weeks of gestational age by dividing the specimens into six gestational age groups (group A to group F) as shown in (Table 1). The observations at different gestational ages are as follows.

Group A (13 – 16 weeks)

At 13 weeks folia could not be identified. Only few shallow grooves were present on the surface. Peripheral dark zone is visible and most probably it is the external granular layer of marginal zone (Fig. 1). At 16 weeks deep groove is observed on the surface indicating the formation of folia. Mantle and marginal zones could be differentiated and external granular layer is present (Fig 2).

Group B (17 – 20 weeks)

At 17 weeks thin external granular layer in the superficial part of marginal zone and thick internal granular layers in its deeper part were observed. Randomly arranged,

rounded or oval shaped Purkinje cells are present in the internal granular layer (Fig.3). At 18 weeks small folia is identified with a deep groove. Darkly stained external granular and lightly stained internal granular layers are clearly demarcated (Fig. 4)

Group C (21 – 24 weeks)

At 22 weeks closely placed folia are visible. External granular and internal granular layers are clearly demarcated. Internal granular layer were containing randomly arranged small rounded Purkinje cells with their small nucleus (Fig. 5) in between other cells. At 23 weeks thin external granular layer and thick internal granular layers are differentiated. Internal granular layer is wider or thicker than the external granular layer. Oval shaped Purkinje cells observed in the internal granular layer (Fig. 6).

Group D (25 – 28 weeks)

At 26 weeks thin external granular and thick internal granular layers are demarcated. A

wider Purkinje cell layer is present in the internal granular layer (Fig. 7). At 27 weeks well differentiated folia and clearly demarcated external granular and internal granular layers (Fig. 8) were identified.

Group E (29 – 32 weeks)

At 30 weeks thin external granular layer and thick internal granular layer is demarcated. Increase in number of Purkinje cells, and their processes were clearly identified. Purkinje cell nucleus could be observed (Fig. 9).

Table: 1: GROUP OBSERVATION OF HISTOLOGY OF CEREBELLUM:

Parameters	GROUP A (13-16)	GROUP B (17-20)	GROUP C (21-24)	GROUP D (25-28)	GROUP E (29-32)	GROUP F (33-36)
Folia	small groove like folia is observed	Present	Present	present	Present	well differentiated folia is present
Mantle zone	Present	Present	-	-	-	-
Marginal zone	Present	Present	Differentiated	Differentiated	Differentiated	Differentiated
EGL	Present but thin	Present	Present	present	Present	Present
IGL	not differentiated	Present	Present	present	Present	Present
Cells in IGL	not differentiated	small rounded cells are randomly arranged	small rounded cells are randomly arranged	Rounded purkinje cells are present	Rounded purkinje cells are present	Pear shaped purkinje cells are arranged in single row

EGL=External granular layer, IGL= Internal granular layer.

Observations in Group F (33 – 36 weeks):

At 35 weeks folia is well differentiated. External granular and internal granular layers are clearly demarcated. Internal

granular layer is wider than external granular layer. Purkinje cells are clearly differentiated along with their nucleus and processes. These are arranged in a single row (Fig 10). At 36 weeks folia are well differentiated. Internal granular layer is wider than the external granular layer. Pear

shaped Purkinje cells are arranged in single row and increase in Purkinje cell number,

processes were observed. The nucleus (Fig. 11) of Purkinje cell is vesicular.

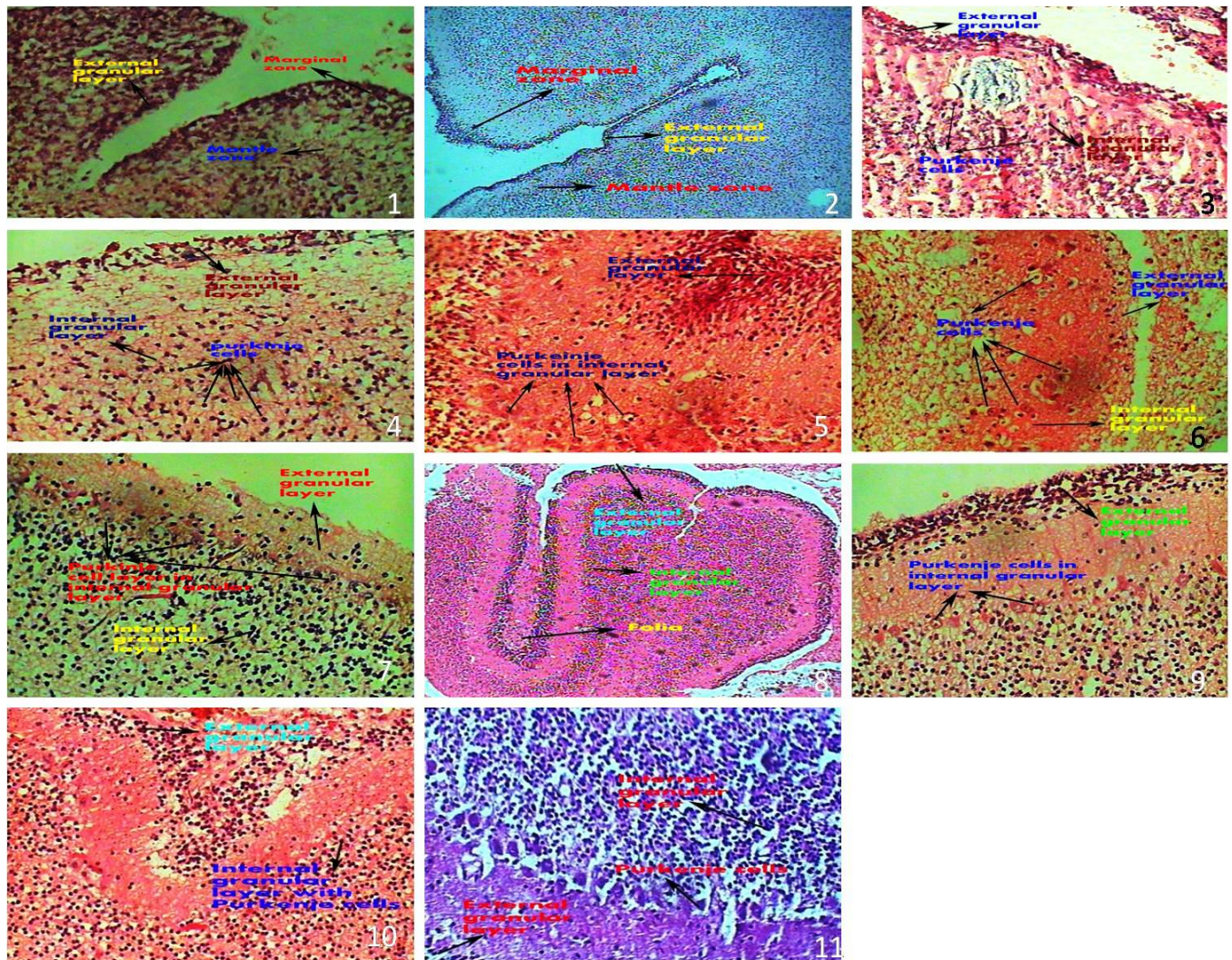


Fig.1.H&E-13 wks(40x). Mantle zone and Marginal zone with External granular layer. **Fig.2.**H&E-16 wks(40x). Deep groove like folia is present and Mantle zone, Marginal zone with External Granular Layer. **Fig.3.**H&E-17 wks(40x). External Granular Layer and Internal Granular Layer present. **Fig.4.**H&E18 wks(40x). Rounded Purkinje Cells present in the Internal Granular Layer. **Fig.5.**H&E 22 wks(40 x).Decreased External Granular Layer and Increased Internal Granular Layer with Purkinje cells. **Fig.6.** H&E 23 wks(40x). Acidophilic stained Purkinje within the Internal Granular Layer. **Fig. 7.**H&E 26 wks(40X). Increased number Cells of purkinje with IGL. **Fig.8.**H&E 27 wks(10x). Internal Granular Layer and External Granular Layer.**Fig.9.**H&E 30 wks(40x). Acidophilic Purkinje cells in Internal Granular Layer.**Fig.10.**H&E 35 wks(40x). Internal Granular Layer with Purkinje Cells. **Fig.11.**H&E36wks(40x). Purkinje cell layer.

DISCUSSION

The differentiation of Purkinje cells and their relationship to other components of the developing cerebellar cortex can be

analyzed by the Golgi impregnation method and by electron microscopy in human specimens of various pre- and postnatal

ages. The three stages of Purkinje cell maturation that have been previously recognized in other species are also evident in man: the first stage occupies primarily the fourth fetal month. During this period (12–16 weeks) differentiation of Purkinje cells and their relationship to other components is observed. The second stage lasts through the fifth, sixth and seventh fetal months (16–28 weeks). The third stage extends throughout the remaining period of intrauterine life and the first postnatal year and continues at a slow rate thereafter. During the first stage, Purkinje cells are distributed in a layer, several rows deep. Their bipolar somas are relatively smooth and have only a few processes at the apical and basal cell poles. In the 3-month period of the second stage, Purkinje cells become gradually organized into a single row (Nada Zecevic et al, 2004).

According to (PaskoRakic et al, 1970) external granular layer was first appeared at 10-11 weeks, purkinje cell population was established in cerebellar cortex by 13 weeks and proved that lamina dissecans was more evident at 20-21 weeks. According to (Zecevic and Rakic, 1976) Purkinje neurons were small and several rows deep between 12 and 16 weeks and they become ordered into a single row, enlarge, and develop increasing complex dendritic branches and synapses, Between 16–28 weeks of gestation. D.Asha latha et al, 2014 was observed the external granular layer as a

single layer at 16 weeks and became 2 layered at 20 weeks and 3 layered at 26 weeks of gestation. External Granular layer is the precursor of the molecular, Purkinje and internal granular layers of the cerebellum.

According to (Yamaguchi et al. 1992) internal granular layer of cerebellar cortex is developed by 3 stages. The primary or undifferentiated stage (before 18 weeks of gestation): In this stage the internal granular layer was hardly distinguishable from layer of immature Purkinje cell. 2. The secondary or intermediate stage (from 18 weeks of gestation to 35 weeks of gestation): In this stage the internal granular layer was clearly visible and almost stable in thickness in all parts. 3. The tertiary or developing stage (35 to 40 weeks of gestation): In this stage the internal granular layer showed dramatic increase in thickness as the formation of cerebellar folia proceeds.

In conclusion, the present study, the mantle and marginal zones of cerebellum were identified at 13 weeks of gestation. A thin external granular layer is observed in marginal zone at 13 weeks. Purkinje cells are present in the internal granular layer and they are multilayered in arrangement at 17 weeks and later the Purkinje cells were beginning to organize in a single layer at 30 weeks and clearly organized in a single layer by 36 weeks of gestation.

REFERENCES

1. Asha Latha D, Deena Usha K, Siva Prasad GV, Ravindra kishore, Lakshmi Kumari K. 2014. Histogenesis of Foetal Cerebellar Cortex. Journal of Dental and Medical Sciences. 3: 23-25.
2. Obersteiner H. 1883. Der feine Bau der Kleinhirnrinde beim Menschen und bei Tieren. Biol Zentralb. 3:145-155.
3. PaskoRakic, Richard I sidman. 1970. Histogenesis of cortical layers in human cerebellum. Particularly the lamina Dissecans. Journal of comparative neurology. 139: 473-500.
4. Popoff S; ZurFrageuber. 1895. Die histogenese der Kleinhirnrinde. Biol. Zentralb. 15: 745-752.

5. Schaper-Alfred. 1894. Die morphologische and histologischeEntwicklung des kleinhirns der Teleostier. AnatAnz. 9: 489-501.
6. Standring S, Harold E, Jeremiah CH. 2008. Gray's Anatomy, Spain .40thedition. Churchill Livingstone. pp. 375- 379, 297- 309.
7. Yamaguchi K., Goto N, Nara T. 1992. Development of human cerebellar granular layer: a morphometric study. No ToHattal Su. 24: 327-334.
8. Zecevic N, RakicP . 1976. Differentiation of Purkinje cells and their relationship to other components of developing cerebellar cortex in man. J Comp Neurol.167; 27-47.